

EFSUMB – European Course Book

Editor: Christoph F. Dietrich

Ultrasound of the liver

Christoph F. Dietrich, Carla Serra², Maciej Jedrzejczyk³

² University of Bologna. ³ Department of Diagnostic Imaging, 2nd Medical Faculty of Warsaw Medical University.

Acknowledgment:

The authors thank Lucas Greiner, Julie Walton, Ioan Sporea, Christian Nolsoe and Norbert Gritzmam for peer review of the manuscript.

Content

Content.....	1
Topographic Remarks.....	2
Liver anatomy.....	3
Ultrasound Examination technique.....	4
Patient Preparation.....	4
Examination.....	4
Liver pathology - diffuse liver disease.....	8
Hepatic steatosis.....	8
Liver cirrhosis.....	9
Chronic viral hepatitis C.....	10
Primary biliary cirrhosis (PBC).....	10
Doppler ultrasound techniques in the evaluation of liver disease.....	11
Anatomy, blood supply of hepatic vessels.....	11
Arterial flow.....	12
Portal venous system.....	12
Venous outflow.....	13
Vascular (Doppler) indices.....	13
Examination of the portal vein in patients with diffuse liver disease.....	13
Normal and pathological portal venous blood flow.....	13
Portal hypertension.....	14
No portal venous blood flow.....	14
Retrograde portal venous blood flow.....	14
Portal vein thrombosis.....	15
Examination of the hepatic veins in patients with diffuse liver disease.....	16
Hepatic venous outflow obstruction (Budd Chiari-syndrome, BCS).....	16
Liver pathology - detection and characterisation of focal liver lesions (FLL).....	16
Liver tumour detection.....	17
Differentiation of benign and malignant lesions.....	18
Focal liver lesion (liver tumour) characterisation.....	19
Liver cyst.....	18
Haemangioma.....	19
Hepatocellular carcinoma (HCC).....	20
Metastases.....	21
Abscess.....	21
Clinical importance of liver ultrasound in daily routine.....	24
References.....	25

Topographic Remarks

The liver is located intraperitoneally, and under the right hemi-diaphragm but also extends across the midline to the left hemi-diaphragm and to the spleen in some cases. The liver is fixed to the diaphragm by the pars affixa and to the ventral abdominal wall by the ligamentum falciforme (falciform ligament) and its strong margin, the ligamentum teres hepatis. The minor omentum consists of the ligamentum hepatogastricum and of the ligamentum hepatoduodenale. The hepatoduodenal ligament carries three vessels – two containing blood (the portal vein and hepatic artery), and one carrying bile (common bile duct). The further courses of these three vessels is mainly parallel (Glisson's triad).

The structures of the liver hilum (porta hepatis) are accompanied by a number of (in relation to the portal vein) ventrally and dorsally located lymph nodes which can routinely be demonstrated by ultrasound (US). The liver has three main veins (hepatic veins) – left, middle and right one – which drain the liver blood to the retroperitoneally located inferior vena cava. The inferior vena cava is variably surrounded by liver parenchyma.

The organs and structures surrounding the liver are the organs of the peritoneal cavity and but also pleural and pericardial structures. Neighbourhood structures adjacent to the liver are numerous, including (clockwise) basal lung portions separated by the muscular layers of the right diaphragm (and more or less extensively also of the left diaphragm too), heart, stomach, intestine (e.g., upper duodenal loop and right colonic flexure), abdominal aorta, inferior vena cava, right adrenal gland and right kidney.

Interposition of the colon between liver and the anterior abdominal wall can prevent the sonographic approach to the right liver lobe in case of Chilaiditi's syndrome. In the case of complete or incomplete situs inversus the topographic relations are inverted.

Liver anatomy

Anatomic orientation

Liver anatomy is defined by ligaments and fissures as well as by the vascular architecture: branches of the hepatic artery, portal vein, and bile ducts in their parallel course define the centers of liver segment anatomy.

Liver segment anatomy

A simplified anatomy divides into the larger right lobe (including segment V, VI, VII, VIII), the left lobe with its medial (IVa,b) and lateral segments (II, III), and the caudate lobe (I).

Couinaud classification

Liver segment anatomy is explained by the widely accepted architecture described by Couinaud [(16;17)]. The Couinaud classification, modified by Bismuth (segment IVa, b), is based on 8 segments, each of which has its own arterial and portal venous vessel

architecture (Glisson`s triad) indicating vascular inflow, outflow, and biliary drainage [(9;10)]. Because of this division into self-contained units, each can be resected (alone or in groups) without damaging those remaining as the vascular inflow, outflow and biliary drainage is preserved. Depending on the 3D volume orientation of the liver (longitudinal or oblique orientated) interpretation of Couinaud classification unfortunately finds some inconsistency in literature. While the portal vein plane has often been described as transverse, it may be oblique since the left branch runs superiorly and the right branch runs inferiorly. In addition to forming an oblique transverse plane between segments, the left and right portal veins branch superiorly and inferiorly to project into the centre of each segment.

Ultrasound Examination technique

Patient Preparation

It is recommended that a patient undergo a period of fasting prior to upper abdominal imaging to maximise the distension of the gall bladder and to reduce food residue and gas in the upper GI tract which may reduce image quality or precluded liver imaging. This is essential for full imaging of the liver and related biliary tree but may not be required in an acute situation such as trauma where imaging of the gall bladder is not immediately essential. A patient may take small amounts of still water by mouth prior to scan, particularly for taking any medications. There is some evidence that smoking can reduce image quality when scanning upper abdominal structures and it is good practice to encourage a patient not to smoke for 6-8 hours prior to US scan. Smoking increases gas intake into upper GI tract and may reduce image quality. Also, some chemicals in tobacco are known to cause contraction of the smooth muscle of the GI tract and this can cause contraction of the gall bladder, even when fasting has occurred, and the gall bladder cannot be scanned.

Examination

The liver is a large, pyramidal shaped organ and liver sectional anatomy may be best described imaged and defined using by real time ultrasound imaging. Conventional real time ultrasound produces images of thin slices of the liver on the screen, and so it is essential that the operator scans the entire organ systematically/ritually, in at least two anatomical planes, to be entirely convinced that the entire volume of the liver tissue and structures has been imaged. The operator must then synthesise this 2 dimensional information in their brain to develop a 3 dimensional map of the individual patient`s liver anatomy and pathology. This requires good hand-eye-brain coordination.

For orientation, three levels of the central portion of the liver can be differentiated:

- Level of the Confluences of the liver veins [Figure 1].
- Level of the Pars umbilicalis of the (left) portal vein branch [Figure 2].
- Level of the gall bladder [Figure 3].

Figure 1 Confluences of the liver veins. This “junction” level is the first one in ultrasound examination of the right liver lobe by subcostal scanning sections steeply “looking” upwards, preferably in deep inspiration [video]. VCI: inferior vena cava. LLV: Left liver vein. MLV: Middle liver vein. C: Confluens of the LLV and MLV. RLV: Right liver vein. The RLV often separately joins the inferior

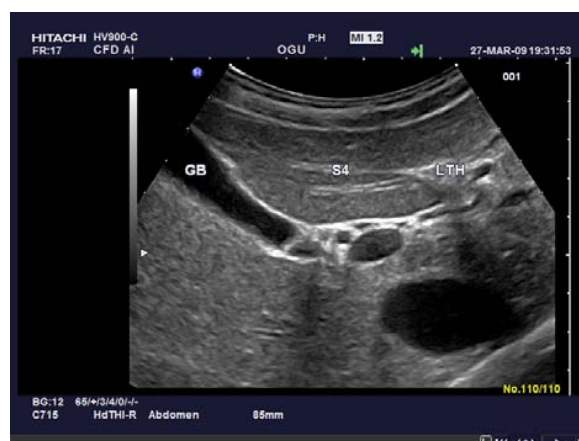
vena cava, whereas the LLV and MLV often reveal a common trunk (“C”).

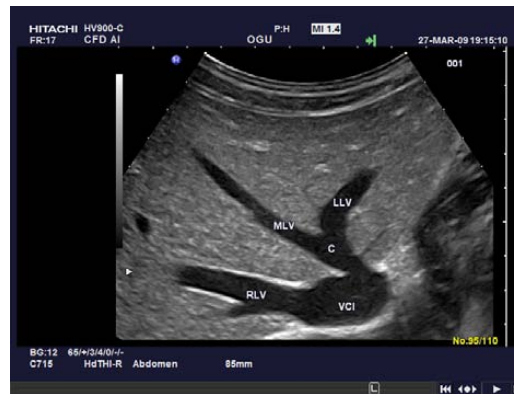

Figure 2 “Pars umbilicalis” of the portal vein – scanning planes display the left and right liver lobes in a more downwards orientated view into the right liver lobe as compared to the level of the confluens of the liver veins. PA: Portal vein. PU: pars umbilicalis of the portal vein. VCI: Inferior vena cava.

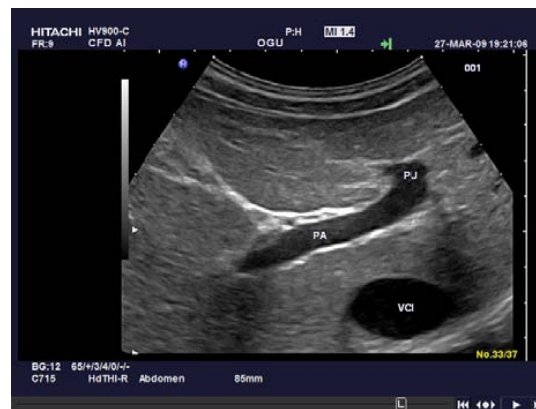

Figure 3 Gallbladder level as the most caudate scanning plane. GB: Gallbladder. LTH: LLigamentum teres hepatis. S4: Segment IV of the liver (quadrate lobe).



Analysing the ultrasound examination, these levels mean the access for a number of (more or less) parallel scanning sections, which in there summary in the examiner`s brain form an real time three dimensional (“4D”) copy of the given patient`s individual anatomy and pathology.

Standardised scanning in a ritualized sequence of probe- and patient positions and of

scanning planes is mandatory to cover all segments and the complete liver surface.

The patient should be examined from sub- and intercostally in the decubitus position as well in modified slightly oblique positions with the right arm above the head and the right leg stretched during all respiration cycles to identify the best approach and to avoid artifacts caused by the thorax. Examination in the standing position is additionally helpful due to its weight, the liver moves caudally by gravity, and scanning from sub- or intercostal probe positions – according to the individual anatomy - avoids the interposed lung which is mainly true for the right posterolateral (superficial) parts of the liver using the intercostal approach. Other examination techniques have also been described but are not mentioned here in detail which might be additionally used.

A great number of variants of the normal has to be encountered – e.g. with respect to accessory lobules, vascular branching, shape and configuration.

Examination criteria

An acronym has shown to be didactically helpful [“SSOTM”]:

- S = size
- S = shape
- O = outline
- T = texture
- M = measurement

Size

The size of the liver has been measured by many methods, including 3D-reconstructions. Liver size measurement has no impact in daily routine because there is no reliable and reproducible ultrasound method established so far.

Shape

Normally described as pyramidal.

Outline

The normal liver surface should be smooth with no lumps protruding or indentations. The inferior liver border in the normal patient should have an acute angled edge. Liver surface border delineation and other ultrasound criteria: Other ultrasound criteria are described in the respective chapters.

Texture, echogenicity

The normal liver parenchyma is of medium homogenous echogenicity, usually slightly darker than the spleen and slightly brighter than the renal cortex independently of the age except in childhood [(32)]. It is essential when comparing the liver with the spleen and renal cortex that the comparison is done at the same depth. Liver surface and vessels borders are smooth and vascular architecture with its classic dichotomy in branching is perceived as a harmonic and detailed aspect. The image of the normal parenchyma varies very little among individuals.

Liver veins

The three liver veins are positioned in between the liver segments. Their course - additionally to the Glisson`s triad - is helpful in defining liver lobes and liver

segments. Number and course of liver veins is somewhat variable [Figure 1].

Portal vein

Formed by the confluents of the splenic and superior mesenteric vein, the portal vein can be sonographically displayed using scans more or less perpendicular to the lower costal margin (orientation might be achieved referring from the right shoulder to the umbilicus), preferably in a left decubitus position and in variably deep inspiration. Intrahepatically, the portal vein bifurcates into a main left and right branch. The first (right) portal vein branch splits into an anterior and into a posterior branch, which itself leads to the segments V – VIII. The latter (left) main portal branch bifurcates into segments II and III and, additionally, into the left medial branches for segments I (caudate lobe), IVa and IVb [Figure 2].

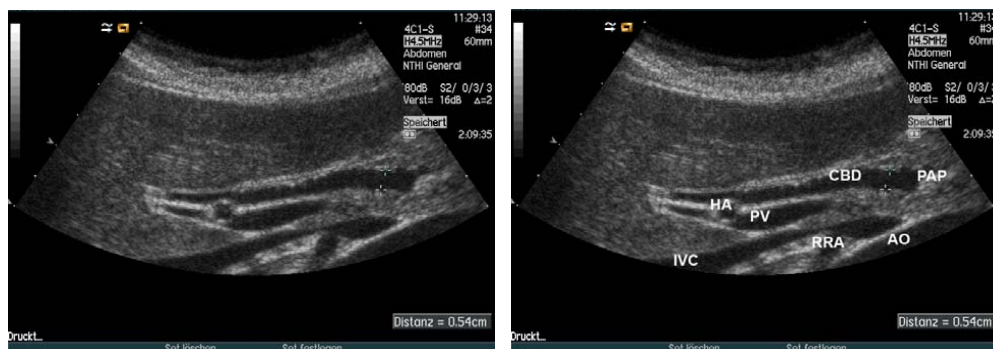
Hepatic artery

The common hepatic artery has its source from the celiac axis, branching into the gastroduodenal artery and into the proper hepatic artery (arteria hepatica propria). Anatomical variations are frequent (in up to 50 %), e.g. the origin of the left proper hepatic artery out of the left gastric artery as well as the variable arterial supply of the liver by superior mesenteric artery branches. The hepatic artery runs with the portal vein, the right main arterial branch frequently meandering around the portal vein sonographically displayed in short segments medially (or less often laterally) of the portal vein. The normal and pathological flow patterns are described below in the Doppler chapter.

Bile ducts

Bile ducts accompany the portal vein and hepatic artery branches from the liver hilum into the liver lobules, intrahepatically forming the ductus principalis dexter and the ductus principalis sinister, which join as common bile duct (CBD). The extrahepatic course of the CBD is cranially (pre-pancreatic) often ventral to the portal vein and caudally (intrapancreatic) more dorsolateral. The respective course of the hepatic artery is more variable [Figure 4].

Figure 4 Common bile duct (CBD). The CBD, and therefore, the liver hilum, is often best examined in a left lateral decubitus position using a subcostal approach in slight inspiration [video]. In the typical view CBD (in between markers), portal vein (PV), hepatic artery (HA), inferior vena cava (IVC) and right renal artery (RRA) (and sometimes also the aorta [AO]) can be seen; the papilla region (PAP) is indicated.



Liver pathology - diffuse liver disease

Criteria for analysing diffuse liver disease include evaluation of

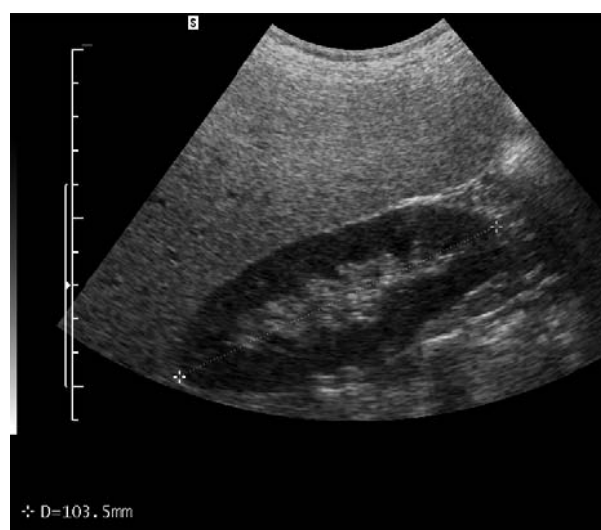
- liver parenchyma (echo texture, ultrasound attenuation, vascular architecture, etc.) as well as its surface (a high frequency transducer is helpful in detecting more details of the superficially located structures);
- liver hilum structures including perihepatic lymph nodes in the hepatoduodenal ligament, lymph nodes in inflammatory liver disease or neoplastic infiltration;
- analysis of hepatic vessel flow patterns using colour and pulsed wave Doppler imaging (CDI).

Ultrasound contrast agents (USCA) have improved the detection/exclusion rate of focal liver lesions; in diffuse liver disease, USCA potential is much lower (e.g., hepatic transit time).

Hepatic steatosis

Hepatic steatosis is the most common liver pathology. Sensitivity and specificity of the detection of hepatic steatosis by B-mode ultrasound examination may be very high in the hands of an expert investigator who consistently applies specific criteria in patients with significant fatty liver disease. In transabdominal ultrasound, hepatic steatosis is characterised by increased echogenicity, which is often compared to the spleen or kidney parenchyma at the same depth [Figure 6]. Supporting findings may be ultrasound attenuation, which means a decrease in intensity as sound travels through a material, caused by absorption, scattering, and beam divergence. Attenuation decreases detail analysis of vascular architecture, and it may cause a loss of visibility deeper within the liver and impeded imaging of the diaphragm.

Figure 6 Hepatic steatosis (fatty liver). Sonographic signs of hepatic steatosis include hepatomegaly with rounded borders, increased echogenicity, ultrasound attenuation caused by absorption, scattering, and beam divergence and decreased detail display of intra-hepatic vascular architecture. There is exaggeration of the difference between the kidney parenchyma and liver echogenicity. Right kidney is shown between callipers (+).



In the majority of patients with hepatic steatosis, distinctive hypoechoic areas in the liver hilum can be demonstrated by ultrasound examination [Figure 7] [(7;28;38)]. It

is believed that the presence of focal hypoechoic areas (FHA) within the liver hilum (and elsewhere in the liver) corresponds to parenchymal islands with (close to) normal fat content (due to a locally different blood supply), that are surrounded and contrasted by bright echogenic parenchyma with fatty infiltration. Subcapsular FHA and FHA close to liver veins are other typical locations, the shape of these “pseudolesions” being polycyclic and non-round. FHA are relatively specific for hepatic steatosis and may be helpful to differentiate fatty from fibrotic liver disease.

Similar focal hypoechoic areas were demonstrated in patients with liver steatosis due to systemic corticosteroid therapy, even though the more important focal lesions in this condition are hyperechoic [Figure 8]. Pathophysiologically areas of different fat content might be explained by a different arterial and portal venous blood supply in comparison to the surrounding liver parenchyma which is mainly portal venous and contains, therefore, a higher fat and insulin concentration in focal fatty infiltration [(32;38)].

Figure 7 Hepatic steatosis. Perhaps the most objective and therefore most important sign of hepatic steatosis are circumscribed focal hypoechoic areas in the liver hilum examined in a left posterior oblique position. B-mode ultrasound demonstrates a focal liver lesion in between calipers (a). Colour Doppler imaging indicates a centrally located vessel of undetermined origin (b).

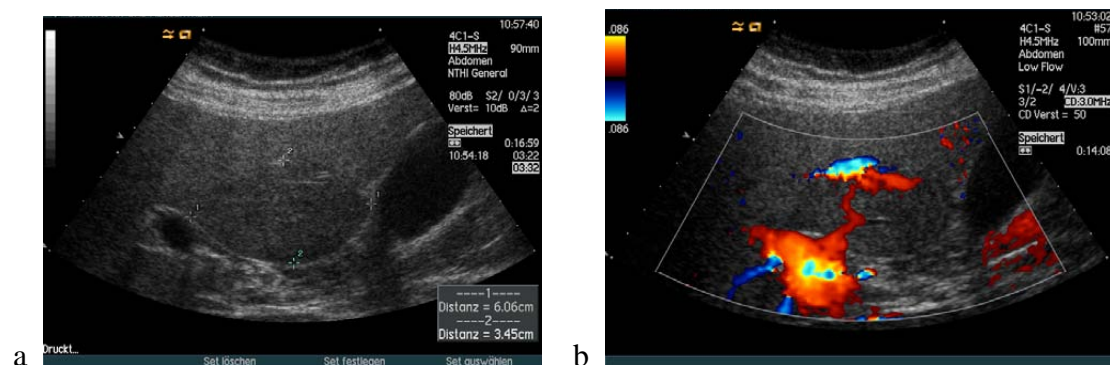
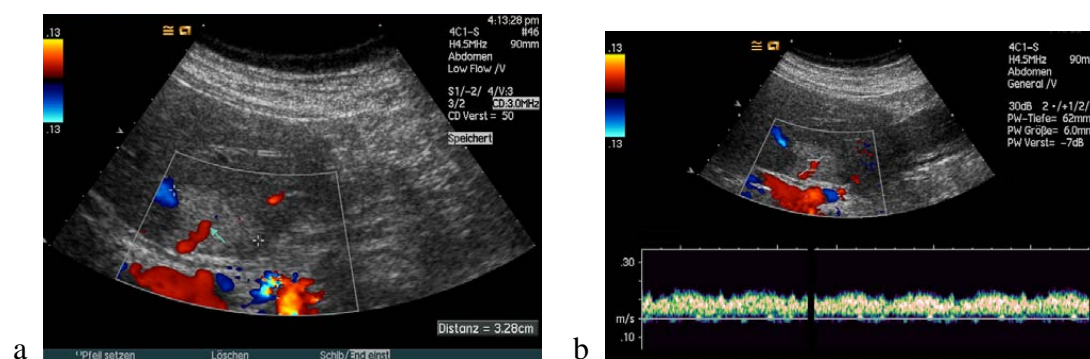


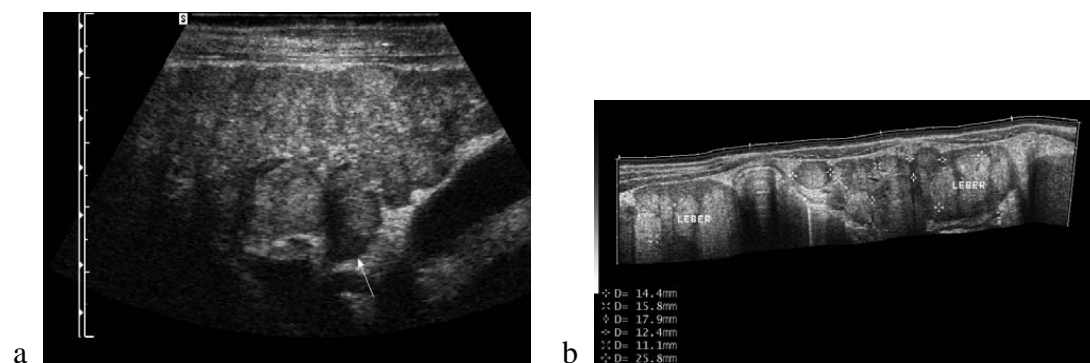
Figure 8 Hepatic steatosis indicated by focal hyperechoic ([28]) areas in the liver hilum. They are characterised by centrally located (portal) vein branches identified by colour Doppler imaging (a), spectral analysis and CEUS (b). Such lesions are also typically found subcapsular next to the teres ligament [(28)].



Liver cirrhosis

The accuracy of ultrasound in the correct diagnosis of “liver cirrhosis” in patients with complications (ascites, splenomegaly, collaterals) is high ($> 90\%$). In the initial stages and in micronodular cirrhosis, it may be overlooked in up to 30% [(32)]. Sonographic signs of liver cirrhosis include inhomogenous echotexture and irregular-nodular liver surface delineation and a variety of other possible findings including destroyed vascular architecture also dependent on the etiology of diseases [Figure 9]. Dysproportional segment atrophy (and also hypertrophy) has been observed [Figure 10].

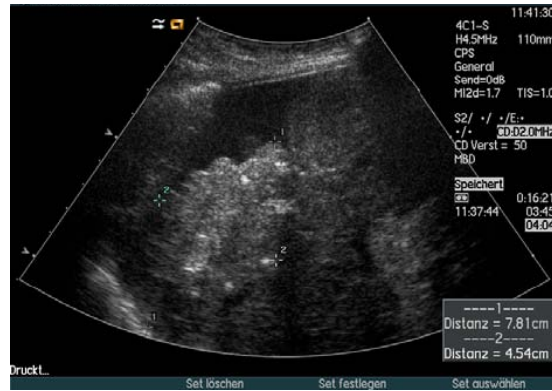Figure 9 Liver cirrhosis. Typical signs of liver cirrhosis include inhomogenous echotexture and irregular liver surface delineation (a, arrow). In addition distinctive nodules are suggestive (b). Sometimes it might be difficult to identify the liver parenchyma, therefore the organ is indicated as well: Leber: liver.



Nodular liver surface (especially using high frequency transducers) has an excellent positive predictive value close to 100% for cirrhosis. A disproportional volume enlargement of the caudate lobe in relation to the right and left lobe may be indicative of liver cirrhosis but this sign is of limited value in daily clinical practice.

Coarse liver parenchyma and a disturbed or destroyed vascular architecture as a sign of portal hypertension - such as reversed portal flow and collateral vessels - are other signs of liver cirrhosis. In Doppler studies, a raise in the arterioportal peak velocity ratio (maximum velocity of the hepatic artery divided through the maximum velocity of the vena portae) of more than 3.5 is predictive for cirrhosis. The positive predictive value of the detection of signs of portal hypertension is excellent such as reversed portal flow and the detection of collateral vessels. The negative predictive value is worse. Overall, the accuracy is about 60% . An enlarged portal vein diameter greater than 1.25 cm or a reduced portal vein flow velocity indicates cirrhosis with a sensitivity and specificity of about 80% . All mentioned parameters, however, are of limited value.

Figure 10 Liver lobes and segments may behave different during the course of a disease, as shown in this patient with systemic sclerodermy with gradually shrinkage of the right liver lobe (in between markers). The changes of the liver evolved gradually over the last ten years.



Chronic viral hepatitis

In patients with chronic viral hepatitis B or C infection, hepatic steatosis is a frequent histological finding, occurring in more than 50 % of cases. The reason for this remains poorly understood. Even when the most common causes of steatosis are carefully excluded, a significant proportion of patients with chronic HCV infection show signs of liver steatosis.

Primary biliary cirrhosis (PBC)

The echo texture of the liver parenchyma in patients with PBC in stages I and II is often unremarkable. In stage IV typical signs of liver cirrhosis are detectable. The liver parenchyma of patients with stage III PBC show advanced sono-morphological modifications like inhomogenous parenchyma but no indicative signs of liver cirrhosis. The extent of perihepatic lymphadenopathy reflects progression of the disease with larger lymph node size in more advanced stages [(25)].

Doppler ultrasound techniques in the evaluation of liver disease

Anatomy, blood supply of hepatic vessels

Two vascular systems with completely different haemodynamics and one outflow system characterize hepatic perfusion:

- Arterial inflow (high pressure, low flow resistance) [Figures 16 & 17]
- Portal-venous inflow (low pressure, low flow resistance) [Figure 18]
- Venous outflow (low pressure and low flow resistance) [Figure 19]

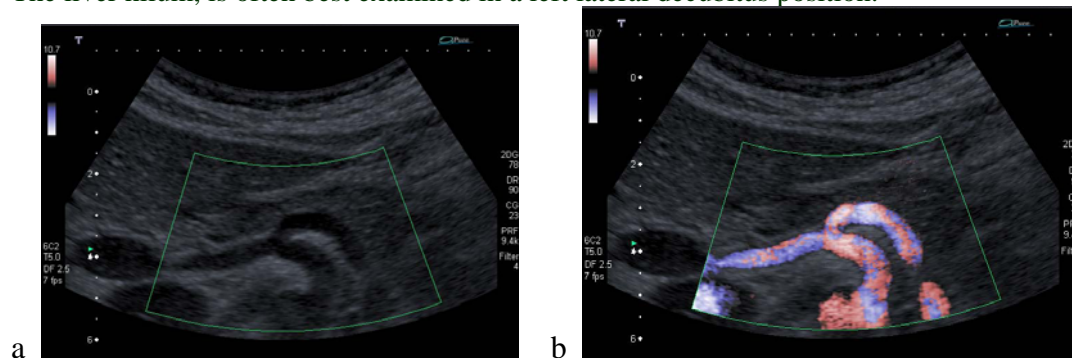
Vascular hepatopathies occur with abnormal vascular courses, aneurysms, stenoses and occlusions of these vessels.

Arterial flow

Arterial liver perfusion disorders are rare, both in the sense of hypo- and hyperperfusion. A diminished arterial blood flow may be caused by congenital malformations as well as by acquired embolic, thrombotic, inflammatory, vascular-tumourous, vasculitic or arteriosclerotic-degenerative changes, or in (acute) myocardial forward failure and shock [(15;40;43;49;50;52)]. Hyperperfusion is observed even less frequently and is caused by arteriovenous shunts which are of congenital (e.g., Osler's disease), traumatic or septic-embolic origin, as examples.

- Hypoplasia and aplasia of the common hepatic artery and/or its branches with atrophy of related liver segments,
- Aneurysms of the common hepatic artery and its branches.
- Atypical vascular courses (e.g. with impression of the hepatic choledochal duct).
- Arteriovenous and arterioportovenous shunts (e.g., occurrence of M. Osler).
- Abnormal hepatic vascular malformations occur more frequently in connection with vascular changes in other organs (heart, lungs, brain, and kidneys) which tend to determine the clinical course and prognosis to a greater extent.

Figure 16 Extrahepatic hepatic arterial vessels. The coeliac trunk (B-mode [a], colour Doppler imaging [b]) is the arterial blood supply for the liver and the perihepatic structures. The liver hilum, is often best examined in a left lateral decubitus position.



Portal venous system

Signs of portal hypertension (splenomegaly, ascites and collateral vessels) with continued liver function impairment are suspected or proven by ultrasound including thrombosis [(3;34-36;40;47-51;53-55;57;58;60-62)]. Its most important disorder is *portal vein thrombosis*.

Venous outflow

With disorders of the venous outflow, first a (substantial) restriction of the liver function occurs and second, signs of high portal vein pressure are detected. *Right-ventricular heart failure* is the most frequent venous outflow disorder. The increase in post hepatic resistance reduces the portal hepatic perfusion and may lead to a pendular or retrograde flow in the portal vein, especially in cases with an additional intrahepatic increase in resistance.

Colour Doppler imaging (CDI) for analysis of hepatic vessel flow pattern – an introduction

CDI is accurate and well established in evaluating portal hypertension, portal vein thrombosis due to different causes, Budd Chiari-syndrome and other forms of veno-occlusive diseases. CDI is routinely used to evaluate patients prior to liver transplantation to determine portal vein patency, signs of portal hypertension, and hepatic artery patency postoperatively. CDI is also important to monitor flow direction and patency of spontaneous and artificial porto-systemic shunts, e.g. TIPSS. Patients after liver transplantation are monitored by analysing the hepatic artery profile. Stenosis and rejection are indicated by changes in the resistance flow pattern.

Chronic heart failure reveals tetra-phasic flow in the right liver vein and highly undulating flow patterns in the portal vein, reversing during intensified therapy.

Analysis of the flow pattern in the liver veins is helpful to characterise diffuse parenchymal liver disease [(4-6)].

Vascular (Doppler) indices

Vascular indices, e.g., Doppler perfusion index (DPI), hepatic transit time and various ratios analysing different vessels have been used for liver tumour detection and characterisation but are currently only used in experimental settings.

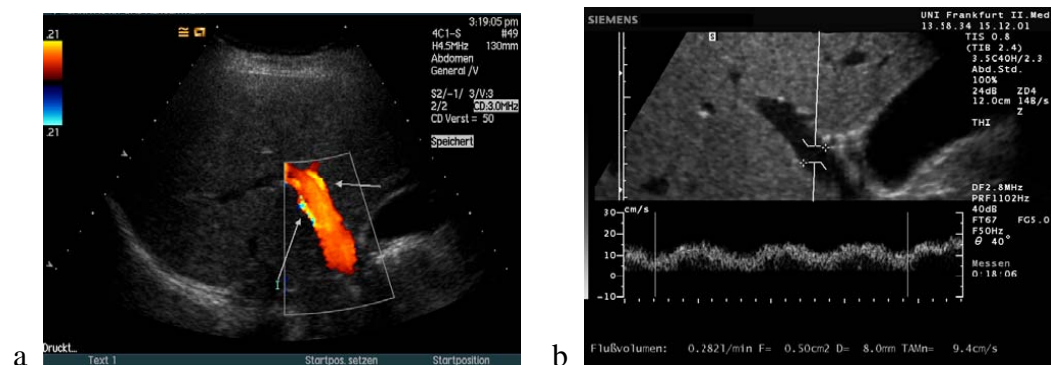
The portal vein congestive index (PVCi) is defined as ratio of cross sectional area of the extra-hepatic portal vein to time averaged mean velocity of blood flow in the portal vein. The PVCi is elevated in liver cirrhosis at an early stage with a constant portal vein blood flow (cross sectional area multiplied by the time averaged mean velocity) which can be reached by an increased portal vein pressure with consecutive dilatation of the latter vessel. The method – more difficult in its wording than in its application after some training – has, however, not been able to reach general acceptance.

The Doppler perfusion index (DPI) is the ratio of hepatic arterial blood flow (normal below 20 %) to the total liver blood flow (hepatic arterial and portal venous blood flow). DPI is reported to be elevated in the presence of intra-hepatic tumours as well as in patients with liver cirrhosis, and was used to screen patients with suspected metastases. The promising data could not be reproduced.

Normal and pathological portal venous blood flow

Normal portal venous blood flow is slightly undulating [normal values 12-24 cm/sec examined by the intercostal approach with a mean resistance index of 0.36]. Different pathological flow patterns of the portal venous system have been described [(21;23)].

Figure 18 Portal vein. The portal vein (arrows) is scanned transcostally shown by colour Doppler imaging (a) and continuous duplex scanning (b) with a normal flow pattern range of 12 – 24 cm/sec [(23)].

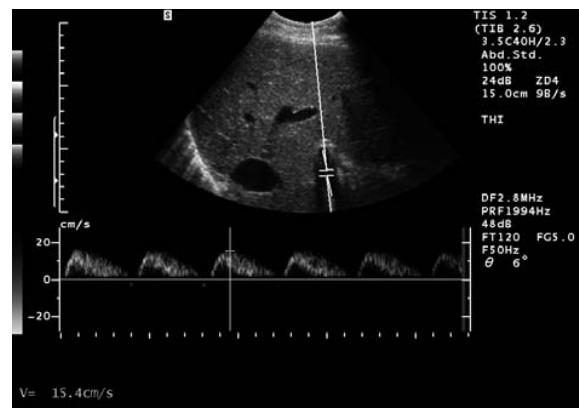


Portal hypertension

Colour Doppler ultrasound examination is recommended in patients with suspected portal hypertension since CDI is helpful in the detection of the presence and direction of blood flow in the portal venous system [(48)]. Hepato-fugal flow in the portal vein is found in about 10 % patients with liver cirrhosis [(40)]. Prevalence does not differ in relation to the aetiology of liver cirrhosis but is stage dependent and could be more often found in Child B and C cirrhosis than in Child A cirrhosis. The clinical significance of this Doppler phenomenon is still unclear, especially with its relation to (repeat) variceal bleeding.

Increased pulsatile flow (high resistance index) in the portal vein has predominantly been found in patients with severe right heart failure, demonstrating right atrial pressure negatively correlated with portal vein pulsatility ratio [Figure 19] [(35;48;50)]. In patients with steatosis the flow is flattened which is demonstrated in a low resistance index.

Figure 19 Increased pulsatility in the portal vein. Increased pulsatile flow in the portal vein has predominantly been found in patients with severe right heart failure, demonstrating right atrial pressure negatively correlated with portal vein pulsatility ratio.



No portal venous blood flow

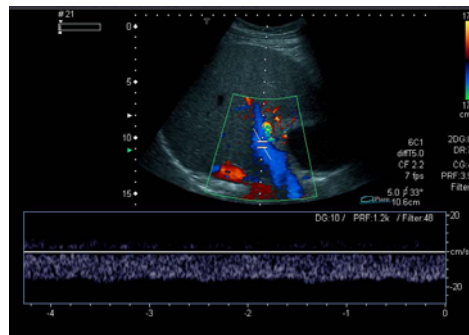
Very slow portal vein velocities of less than 2 cm/sec are difficult to detect because this Doppler signal is lower than the threshold of the ultrasound equipment and additional respiratory modulation of the patients. A stagnant or portal venous "0" flow is mainly seen in patients with advanced liver cirrhosis. In patients with stagnant portal vein flow the use of ultrasound contrast enhancing agents might be helpful in the exclusion of portal vein (appositional) thrombosis [(41)].

Retrograde portal venous blood flow

Reversed portal venous blood flow can be observed when intra-hepatic resistance is greater than the resistance of porto-systemic collaterals [Figure 20]. An association has been found between portal venous flow patterns (e.g., abnormal flow direction) and the presence of mainly spontaneous porto-systemic shunts but also oesophageal varices and ascites. The increase of intrahepatic resistance might be explained by structural abnormalities, e.g., hepatocyte enlargement, Disse space collagenisation and hepatic vein sclerosis. Retrograde portal venous flow has been observed mainly in patients with portal hypertension. Respiration dependent hepato-fugal portal flow is a rare finding associated with periodic portal hypertension in patients with right heart insufficiency and/or liver disease. Its clinical significance is unclear.

Pericardial effusion, constrictive pericarditis, pericardial tumours and right atrial tumour and possible other causes leading to an increased right atrial pressure are responsible for a pressure-related hepatic venous out-flow block with subsequent trans-sinusoidal hepato-portal shunting, similar to the mechanical outflow block that causes reversed pulsatile flow in liver cirrhosis. Severe pulmonary hypertension may be responsible for a second important pathophysiological mechanism. Portal vein–hepatic vein shunts and portocaval (portosystemic) shunts may also cause pulsatile portal flow.

Figure 20 Retrograde portal venous blood flow as a typical sign of severe portal hypertension.



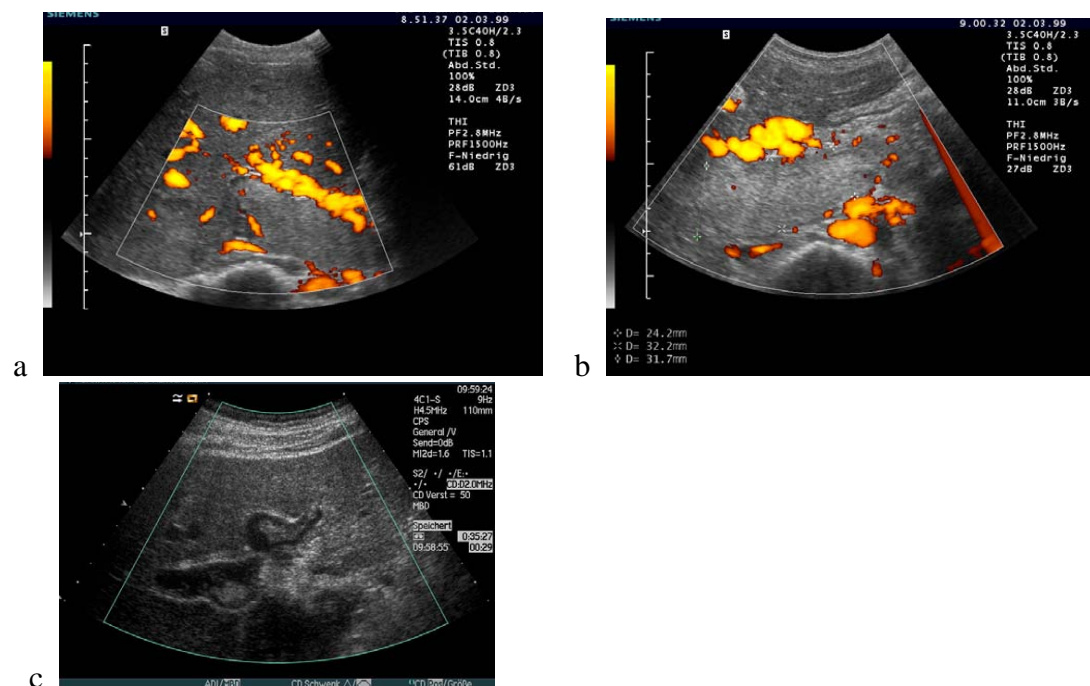
Portal vein thrombosis

Portal vein occlusion with an increase in pre-hepatic portal vein pressure may have different causes – coagulation defects with thrombocytosis, an increase in fibrogen concentration due to inflammation and similar conditions have to be encountered.

Periportal venous collaterals as cavernous transformation may at least partially compensate the portovenous hepatic inflow. Moreover, reduced portovenous blood supply may be compensated by an increased arterial perfusion so that the liver function usually appears only slightly impaired. Portosystemic collaterals, however, lead to a reduced “first-pass” effect, deteriorating e.g. encephalopathy. This is especially important when portal vein thrombosis is caused by cirrhosis with reduction of flow, since because of this, encephalopathy may become manifest and the liver-dependent medication metabolism may be disturbed.

Colour-coded duplex sonography is the method of choice and has a high degree of sensitivity (> 90 %) in detecting segmentally localized or complete portal venous thrombosis [Figure 21].

Figure 21 Portal vein thrombosis. Echogenic and total portal vein thrombosis intrahepatically (a) and also extrahepatically (b). Circumscribed portal vein thrombosis is shown in B-mode ultrasound (c).



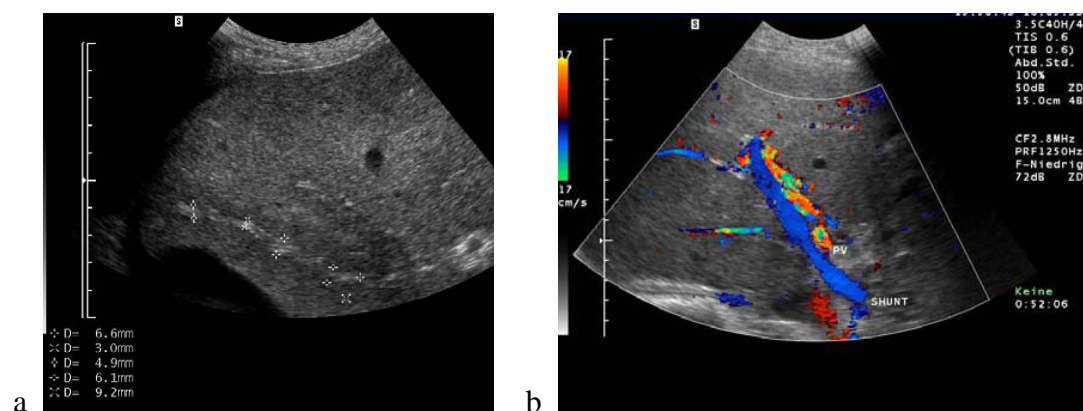
Contrast enhanced computed tomography is an alternative in the diagnosis of portal vein thrombosis, especially with obese patients. Magnetic resonance tomography and splenic portography are unnecessary.

Before operations or interventions it may be desirable to perform angiography of the visceral vessels. Ultrasound is specific for exclusion of infiltration of hepatic vessels (e.g. portal vein and hepatic veins). Portal vein thrombosis is a common sign of tumour angiogenesis, especially in extensive tumour stages. To differentiate between benign and malignant portal and hepatic vein thrombosis it is useful to use colour Doppler imaging or contrast enhanced techniques. Using colour Doppler imaging malignant infiltration can be assumed, if pulsatile flow is derived from inside of the thrombus. If this is not conclusive, contrast enhanced ultrasound is more sensitive in showing arterial enhancement of the thrombus.

Hepatic venous outflow obstruction (Budd Chiari-syndrome, BCS)

Budd-Chiari syndrome is a rare cause of liver disease with or without signs of portal hypertension. About one third of patients present with acute disease with sonographically detectable thrombosis. About two thirds have chronic presentation sonographically with occluded hepatic veins and intrahepatic collaterals [Figure 23].

Figure 23 Budd Chiari syndrome. About one third of patients present with acute disease with sonographically detectable thrombosis. About two thirds have chronic presentation sonographically with occluded hepatic veins (a, in between markers), retrograde portal venous outflow (b), and intrahepatic collaterals with or without extrahepatic shunts. PV: portal vein.



The hepatic vein might in this stage be occluded appearing as fibrous strand or spontaneously partially or completely recanalised depending on the etiology. Colour Doppler imaging is helpful in the diagnosis of BCS. Doppler ultrasound accurately detected the site of the block in 31 of 39 patients (79%). In patients with newly diagnosed Budd-Chiari syndrome hepatocellular carcinoma has to be ruled out by contrast enhanced ultrasound or other imaging methods.

Liver pathology - detection and characterization of focal liver lesions (FLL)

The definition of a focal liver lesion (FLL) is differences in echogenicity between a circumscribed area and the surrounding liver tissue. Differences in ultrasound echogenicity usually, although not necessarily, show more or less pronounced differences in X-ray attenuation and in magnetic resonance (MR) as well. Consequently, most FLL are visualized by all three sectional imaging modalities, whereas some few are shown by one or two of these modalities only.

FLL are detected and characterised sonographically by echogenicity differences from the surrounding liver tissue as well as by the detection of hyper- or hypovascularisation (colour Doppler ultrasound).

Conventional B-scan ultrasound makes it possible to detect unequivocally the frequently occurring typical liver cysts and calcifications. Detection and characterisation of liver tumours on the other hand, still represents a challenge to all imaging modalities despite all the advances in imaging techniques (ultrasound, CT and MRI scanning).

More recently, contrast enhanced ultrasonography can provide important additional information on FLL perfusion kinetics and vascularisation pattern. Circumscribed lesions of liver-foreign tissue (e.g. metastases) can be detected by the absence of uptake of contrast media.

Such lesions appear in the post vascular late-phase image as storage defects, though this late-phase effect is neither absolutely specific nor absolutely sensitive. As a result of their doubled blood supply via the portal vein and the hepatic artery, focal lesions in the liver often exhibit no general hyper- or hypo perfusion but, depending on the flow phase and the histology, present a complex temporal and spatial picture of increased and reduced contrast. Certain lesions can give a characteristic vascular picture (e.g. the wheel-spoke phenomenon) or a distinctive perfusion pattern (e.g. halo contrasting or iris diaphragm phenomenon), allowing the lesions to be characterised, but the contrast patterns do not always take this typical form. Similar arterial, parenchymatous, and venous characteristics are exhibited by the spleen and by lymph nodes.

The technique of contrast enhanced ultrasound (CEUS) is described in the technical chapter. The use of contrast agents in the liver is possible for different purposes [(14;18)]:

- detection of liver tumours;
- characterisation of liver tumours (benign versus malignant);
- monitoring of local ablative treatment;
- imaging hepatic vessels;
- describing diffuse liver disease by demonstrating intrahepatic microscopic shunts by measuring the hepatic transit time (time interval between appearance in the hepatic artery to the liver veins);
- Analysing time intensity curves.

Liver tumour detection

CEUS increases the detection rate of metastases as compared to conventional B-scan ultrasound which has been demonstrated also by multicenter trials. Comparative studies have shown that the detection rate is of the same accuracy as the detection rate for contrast enhanced CT and MRI scans.

CEUS allows the same detection rate for benign FLL as compared to their occurrence in normal liver parenchyma (10 % of all livers) which is of importance when it comes to a differential diagnosis.

Differentiation of benign and malignant lesions

Characterisation of a liver lesion begins once an abnormality is found. An imaging procedure that is used to detect liver masses should also enable the examiner to differentiate between benign and malignant lesions. Contrast enhanced ultrasound in the portal venous and late phase after injection of Levovist[®] and SonoVue considerably improves the characterisation of liver tumours compared with conventional B-mode ultrasound, leading to differentiation of benign and malignant liver lesions in most patients - if cysts and calcifications are excluded by conventional B-mode ultrasound. CEUS facilitates the clinical decision as to whether a sonographically detected liver lesion will need further investigation or not. From this point of view, this new technique might help to reduce unnecessary or invasive examinations in certain cases, such as invasive liver biopsy, CT-scan and MRI. Only few false positive findings have been observed so far, mainly due to abscesses or necrosis, old fibrous focal nodular hyperplasia with predominantly scar tissue, sarcoidosis lesions, and inflammatory pseudo-tumours of the liver [(20)].

Focal liver lesion (liver tumour) characterisation

Liver cyst

Liver cysts are a frequent finding. They are readily diagnosed using conventional B-mode ultrasound. Liver cysts are characterised, as other cysts by - typically round, anechoic, smoothly delineated structures with refraction shadows at the edges, strong posterior wall echo and postcystic enhancement due to the intensity difference between the beam intensity deep to the cyst and in the cysts displaying all sonographic sign are defined as typical [Figure 25] whereas cysts with not all sonographic signs of typical cysts are defined as being atypical [Figure 26].

Figure 25 Typical liver cyst. Exophytic liver cyst next to the spleen. Typical liver cysts display all morphological criteria (echo-free, round-oval, well-defined borders with lateral shadowing and transducer distal (posterior) echo enhancement) whereas atypical liver cysts do not.

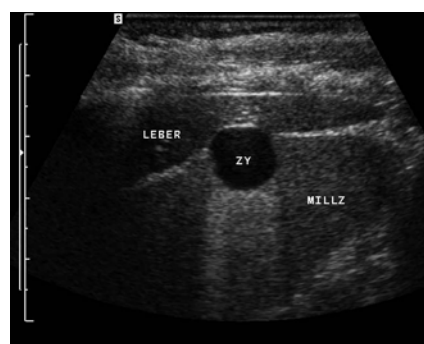
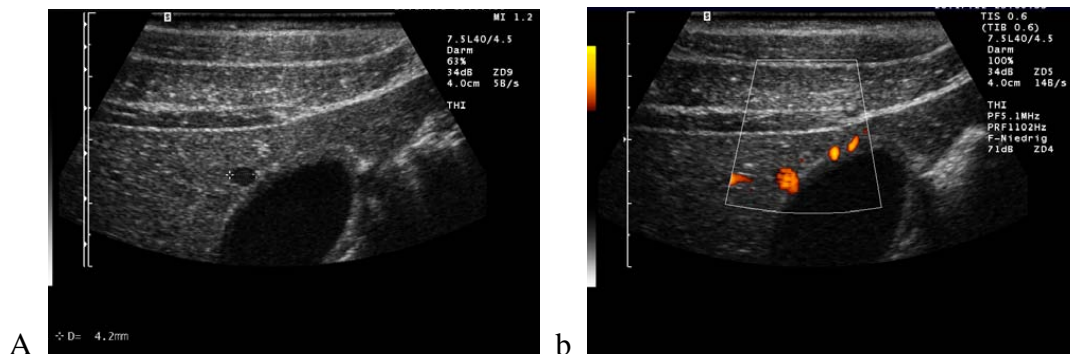


Figure 26 Atypical liver cyst. Atypical liver cysts do not display all morphological criteria of typical liver cysts (echo-free, round-oval, thin walled, well-defined borders with lateral refraction shadowing and postcystic echo enhancement). In another example the cyst like structure is a hepatic vessel which might be sometimes difficult to recognise using conventional B-mode (a,b).



Haemangioma

Hepatic haemangiomas are known to be the most common benign liver tumours, with an incidence in autopsy and imaging studies of up to 7 % [Figure 30-32]. Up to 10 % of patients with haemangiomas cannot be reliably diagnosed using imaging methods; in those patients only ultrasound guided liver biopsy and examination of the specimen is decisive for final diagnosis which is mainly true in the patient with malignant underlying disease. One retrospective study of percutaneous biopsies of 38 patients (1 cm to 13.5 cm, with a mean of 3 cm) with suspected hemangioma using 20 gauge needles reported that it is safe and effective for establishing the diagnosis of hemangioma.

Conventional B-mode ultrasound

Most haemangiomas demonstrate typical sono-morphological features in conventional B-mode, characterised as: less than 3 cm in diameter, lobulated with a well defined outline, located adjacent to liver vessels, demonstrating an echo-rich texture and sometimes posterior acoustic enhancement due to blood filled capillaries.

Colour Doppler imaging

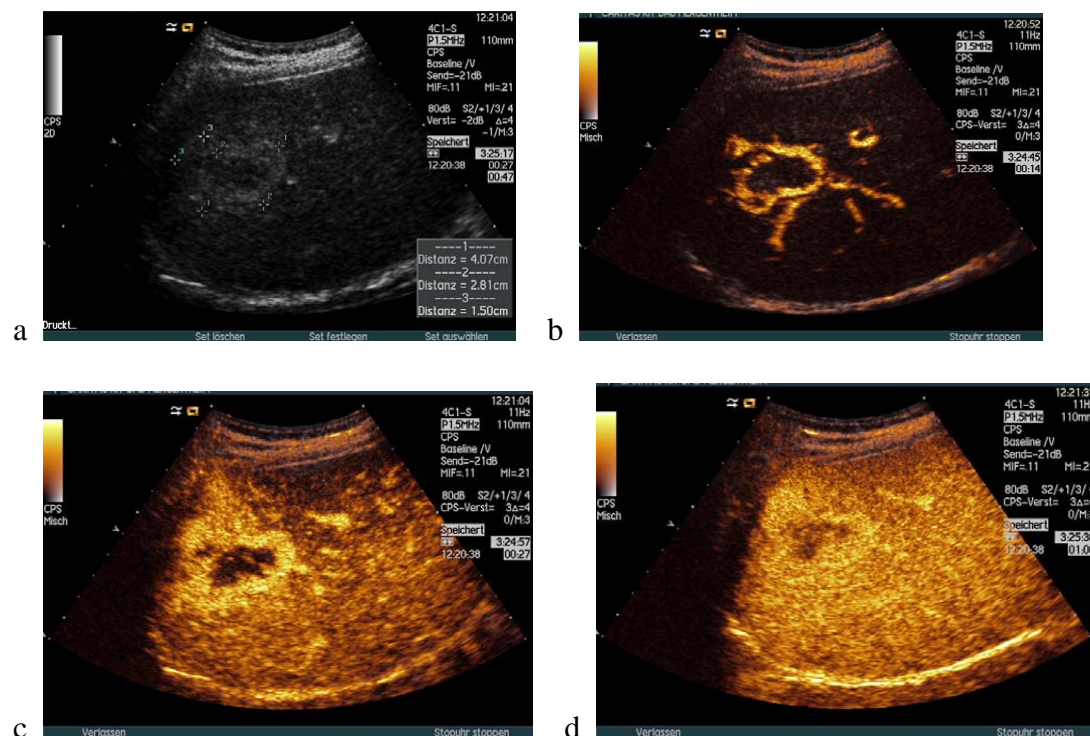
Although haemangiomas are highly vascularised masses, from the histo-pathological perspective, they consist essentially of a large number of capillary-sized vessels and so, even with the use of high-end ultrasound systems, conventional colour Doppler ultrasound often detects little or no blood flow inside the haemangioma due to the fact that the blood flow velocity in the capillary haemangioma is too slow. The supplying and draining vessels (“feedings vessels”) may be visualised (depending on the ultrasound systems performance) at the edge of the lesion.

Contrast enhanced ultrasound

Contrast enhanced ultrasound has markedly improved the correct diagnosis of haemangioma which is possible in about 95 % of patients. CEUS demonstrates typical haemangioma imaging characteristics, i.e. peripheral nodular contrast enhancement and iris-diaphragm sign in a high percentage of patients with undetermined lesion. Difficult differential diagnosis includes shunt haemangioma (synonymous high-flow

haemangioma, 5-10%) which might be confused with focal nodular hyperplasia when small, hepatocellular adenoma or hepatocellular carcinoma. A thrombosed haemangioma might be confused with a metastasis by demonstrating contrast sparing in the arterial and portal venous phase.

Figure 30 Haemangioma. The typical contrast-enhanced ultrasound findings are peripheral nodular contrast-enhancement and centripetal fill in with the exception of thrombosed areas and calcifications (iris diaphragm phenomenon) (between callipers).



Hepatocellular carcinoma (HCC)

Conventional B-mode ultrasound

There are no typical criteria in B-mode ultrasound in small hepatocellular carcinoma < 30 mm. Echogenicity of the lesion depends on its size and on the surrounding liver tissue (cirrhotic versus non-cirrhotic) [Figure 35-36]. HCC in an otherwise normal liver parenchyma is usually iso- or slightly hypoechoic compared to the surrounding liver tissue. Hepatocellular carcinoma can be very difficult to identify in patients with liver cirrhosis and tumours morphology might be iso- hypo- or hyperechoic. Dysplastic nodules are sometimes difficult to differentiate.

Colour Doppler imaging

HCC are in most cases (80-90%) distinctly hypervascularised using conventional colour Doppler imaging [Figure 35] and are mainly peripherally located. In such cases, confusion is possible with other hyperperfused liver tumours which, however, are rarely observed in a cirrhotic liver. From the differential diagnostic point of view it is then necessary to consider metastases of hyperperfused tumours, e.g. a hypernephroma, breast carcinoma, lung cancer, or more typically carcinoids. Metastases of primary extrahepatic tumours are however rare in a cirrhotic liver.

Contrast enhanced ultrasound

HCC typically exhibit hyperperfusion of the tumour compared with the surrounding liver tissue at a time when in the surrounding liver no contrast effect is as yet discernible. In the HCC a chaotic vascular pattern is typically observed, as a sign of neovascularisation of the tumour. Regenerative nodules may also exhibit additional arterial enrichment; by analysis of the portal venous phase it may be possible to differentiate these (isoenhancing) nodules from hepatocellular carcinomas (weakly contrasting).

Sonographic recognition of hepatocellular carcinomas in liver cirrhosis can be difficult if the echo texture is very inhomogeneous. One possible approach is to examine the liver in the early arterial phase after the injection of a signal enhancer, with low mechanical index (<0.4). CEUS has proven to be effective in the differential diagnosis of cirrhotic nodules (regenerative nodule, hyperplastic nodule).

Figure 35 Hepatocellular carcinoma. Hypoechoic (more common) hepatocellular carcinoma with typically peripheral located hypervascularity using colour Doppler imaging.

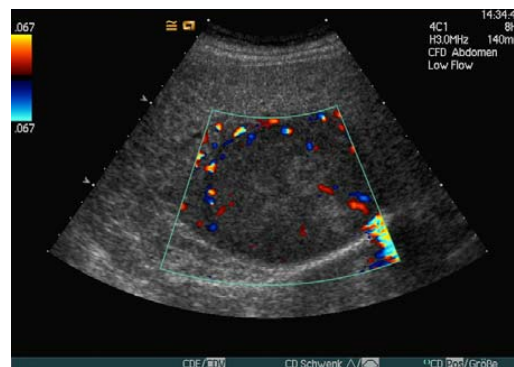
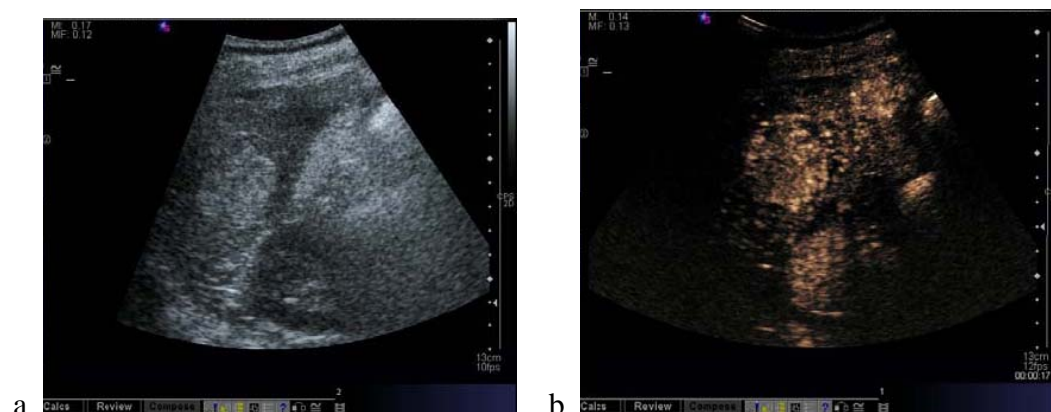
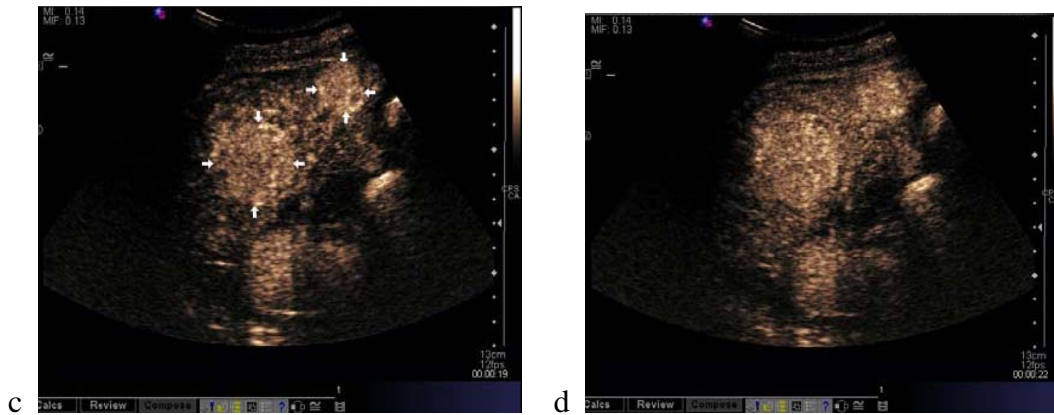


Figure 36 Hepatocellular carcinoma. Hyperechoic hepatocellular carcinoma with arterial enhancement. A satellite is shown as well not easy to recognise using B-mode.





Metastases

The liver is the parenchymatous organ in which metastases of extrahepatic tumours are encountered most often. The special features of portal vein circulation favour haematogenic metastatisation in the liver.

Conventional B-mode ultrasound

Size of the metastases can be anywhere between only microscopically detectable (cellular) infiltration and giant masses measuring more than 20 cm, and the echogenicity varies widely. Intraoperative ultrasound (IOUS) might be helpful in certain cases during surgery.

Colour Doppler imaging

Metastases are as a rule poorly vascularised analysing large definable vessels and their essential characteristic is a predominantly arterial blood supply (with little or no portal venous blood supply). Like the echogenicity (most often hypoechoic), the vascularisation depends on the size, the biological behaviour, and nature of the primary tumour. Irregular vascularisation is often observed, with broken-off vessels and peripherally situated arterio(porto-)venous shunt formation. The metastases of neuroendocrine tumours (and also e.g. metastases of renal cell carcinomas) may be more richly vascularised than other metastases. However, no conclusions are possible about the primary tumour on the basis of the echotexture and vascularisation pattern observed.

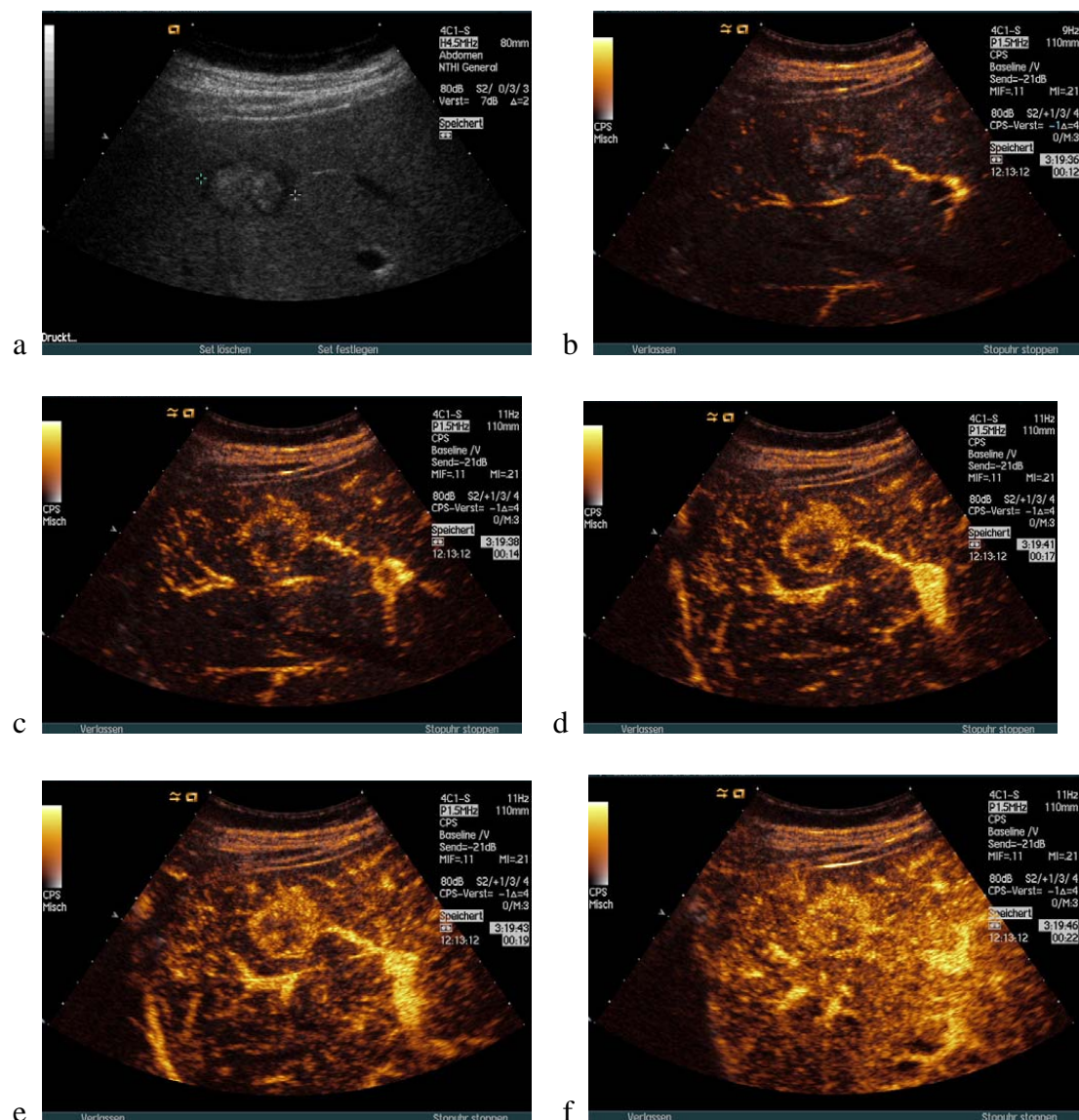
Contrast enhanced ultrasound in metastatic disease

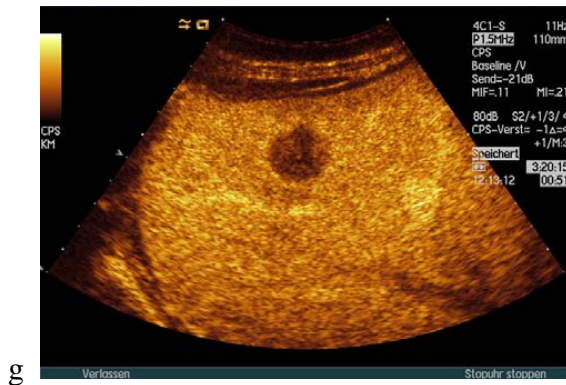
Contrast enhanced ultrasound has markedly improved the detection rate of liver metastases. Liver metastases can be reliably diagnosed as hypoenhancing lesions during the liver specific portal venous sinusoidal phase. False negative findings are rarely encountered whereas false positive findings have to be ruled out by puncture and histological examination, e.g. abscess, necrosis, fibrous tissue and others [(22;59)].

Metastases may be contrasted already in the arterial phase, even though early arterial enhancement (in less than 15 seconds) is not typical and often the only observation is a degree of signal enhancement with a marginal emphasis (“halo sign”, “rim sign”). Contrasting of the vessels proceeds from the periphery towards the centre, and the

vascular pattern is irregular. In poorly vascularised metastases contrast enhanced colour Doppler ultrasound also often reveals only small blood vessels situated at the edges (or within the lesion), and in many patients vascularisation cannot be imaged at all. In the portal venous phase metastases are contrasted increasingly as signal “black spots” against the background of uniformly enhanced normal liver tissue [Figure 39]. Contrast enhanced intraoperative ultrasound might be helpful in certain cases to detect lesions during surgery.

Figure 39 Metastases have a wide variety of B-mode appearances and can be confused with any kind of liver lesion (a). Colour Doppler imaging is helpful in only few patients. Hypervascular metastases reveal the typical peripheral rim sign using CEUS in the arterial phase (b-f) which can also be encountered sometimes in hepatocellular adenoma and hepatocellular carcinoma, and is, therefore, not pathognomonic. Metastases typically exhibit a sharp contrast to normal liver tissue in the liver specific portal venous (sinusoidal) phase (g).





g

Abscess

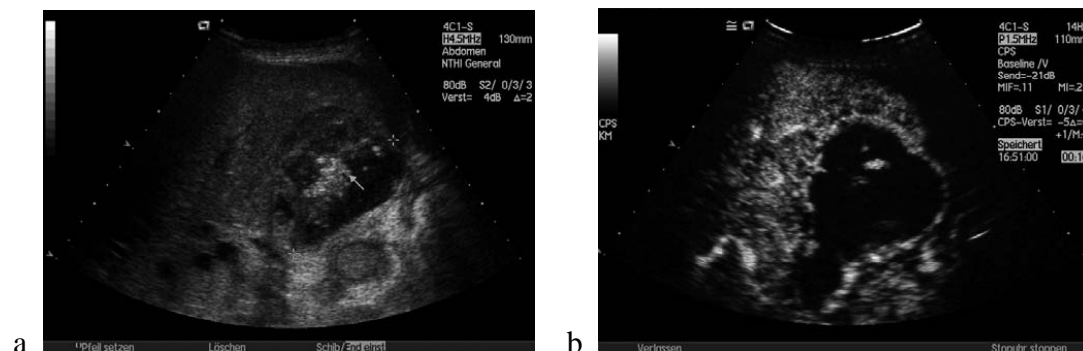
The patient's medical history and sometimes also physical examination (febrile temperature, signs of sepsis) are most helpful in differentiation from necrotic metastases [(20;56)].

Phlegmonous inflammation and abscesses demonstrate variable and sometimes confusing B-mode images changing over time. The initial phlegmonous inflammation is often isoechoic in comparison to the surrounding liver parenchyma and is sometimes difficult to recognise. In older (chronic) abscesses hypervascularity of the nodule border might be confused with pseudotumour of the liver, even histologically. Small disseminate candida abscesses might be confused with lymphoma or circumscribed hemophagocytosis syndrome (especially in the young). Puncture and drainage (if necessary) are the diagnostic and therapeutic interventions. Abscesses up to 5 cm might be drained by one procedure whereas larger abscesses need to be treated over a number of days.

The initial phlegmonous inflammation is often hypervascular in comparison to the surrounding liver parenchyma but difficult to recognise. In older (chronic) abscesses hypervascularity of the nodule border is typical [Figure 41].

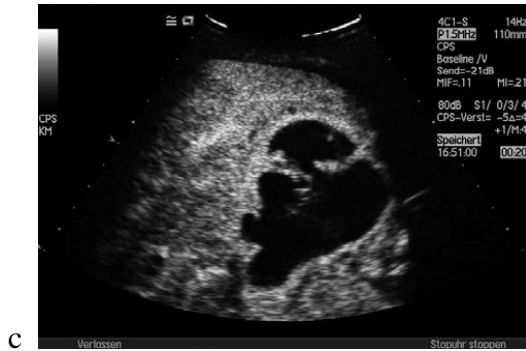In typical cases CEUS shows sharply delineated hypervascularity demonstrating the pseudocapsule and no gas bubbles inside the lesion.

Figure 41 Liver abscess. Typical liver abscesses demonstrating gas inside the lesion (a, arrow). In CEUS, there will be no central signal at all but a pronounced hyperperfusion at the abscess border (b-c). The underlying cause in this patient – choledocholithiasis - is detectable as well (not shown).



a

b



Clinical importance of liver ultrasound in daily routine

Ultrasound is the first and most important imaging method in suspected liver disease – which holds true both in the sense of proving (e.g., metastatic disease) and excluding pathology. It is the single best tool in the evaluation of focal liver lesions, unbeaten by any other imaging modality, due to realtime, dynamic nature, high resolution and good safety record. It is invaluable in the differential diagnosis of jaundice, in describing liver cirrhosis complications, and in any form of ultrasound guided intervention. In summary ultrasound is an indispensable tool in clinical hepatology.

Ultrasound of the liver:

- is the first and most important imaging method in suspected liver disease;
- is first line indication in:
 - o evaluation of elevated liver functions tests and cholestasis indicating enzymes;
 - o differential diagnosis of icterus (diagnosis / exclusion of cholestasis);
 - o monitoring of complications of liver cirrhosis (ascites, portal hypertension, HCC);
 - o tumour detection / exclusion / follow up;
- Contrast enhanced ultrasound is helpful especially for tumour detection and characterisation; it prevents unnecessary further imaging.

Liver sonography is essential for guidance of liver/biliary tree interventions such as biopsy.

Sonography is the most important imaging method in oncological follow up.

The use of sonography is limited in:

- the exact measurement of the size of the liver (which is of limited value in the clinical routine);
- the diagnosis of early cirrhotic stages and in the differential diagnosis of diffuse parenchymal diseases.

References

1. Guidelines for treatment of cystic and alveolar echinococcosis in humans. WHO Informal Working Group on Echinococcosis. Bull World Health Organ 1996; 74(3):231-242.
2. International classification of ultrasound images in cystic echinococcosis for application in clinical and field epidemiological settings. Acta Trop 2003; 85(2):253-261.
3. Abraldes JG, Gilabert R, Turnes J, Nicolau C, Berzigotti A, Aponte J et al. Utility of color Doppler ultrasonography predicting tips dysfunction. Am J Gastroenterol 2005; 100(12):2696-2701.
4. Abu-Yousef MM. Duplex Doppler sonography of the hepatic vein in tricuspid regurgitation. AJR Am J Roentgenol 1991; 156(1):79-83.
5. Abu-Yousef MM. Normal and respiratory variations of the hepatic and portal venous duplex Doppler waveforms with simultaneous electrocardiographic correlation. J Ultrasound Med 1992; 11(6):263-268.
6. Abu-Yousef MM, Milam SG, Farner RM. Pulsatile portal vein flow: a sign of tricuspid regurgitation on duplex Doppler sonography. AJR Am J Roentgenol 1990; 155(4):785-788.
7. Aubin B, Denys A, LaFortune M, Dery R, Breton G. Focal sparing of liver parenchyma in steatosis: role of the gallbladder and its vessels. J Ultrasound Med 1995; 14(2):77-80.
8. Barreiros AP, Otto G, Ignee A, Galle P, Dietrich CF. Sonographic signs of amyloidosis. Z Gastroenterol 2009; 47(8):731-739.
9. Bismuth H. Surgical anatomy and anatomical surgery of the liver. World J Surg 1982; 6(1):3-9.
10. Bismuth H, Houssin D, Castaing D. Major and minor segmentectomies "reglees" in liver surgery. World J Surg 1982; 6(1):10-24.
11. Bleck JS, Gebel M, Witt B, Schmitt KJ, Breilkopf P, Westhoff-Bleck M et al. Sonography under Daylight Conditions. Ultraschall Med 1998; 19(6):259-264.
12. Braden B, Faust D, Ignee A, Schreiber D, Hirche T, Dietrich CF. Clinical relevance of perihepatic lymphadenopathy in acute and chronic liver disease. J Clin Gastroenterol 2008; 42(8):931-936.
13. Caselitz M, Wagner S, Chavan A, Gebel M, Bleck JS, Wu A et al. Clinical outcome of transfemoral embolisation in patients with arteriovenous malformations of the liver in hereditary haemorrhagic telangiectasia (Weber-Rendu-Osler disease). Gut 1998; 42(1):123-126.
14. Claudon M, Cosgrove D, Albrecht T, Bolondi L, Bosio M, Calliada F et al. Guidelines and good clinical practice recommendations for contrast enhanced

- ultrasound (CEUS) - update 2008. *Ultraschall Med* 2008; 29(1):28-44.
15. Colli A, Cocciolo M, Mumoli N, Cattalini N, Fraquelli M, Conte D. Hepatic artery resistance in alcoholic liver disease. *Hepatology* 1998; 28(5):1182-1186.
 16. Couinaud C. The parabiliary venous system. *Surg Radiol Anat* 1988; 10(4):311-316.
 17. Couinaud C. The anatomy of the liver. *Ann.Ital.Chir.* 63(6), 693-697. 1992.
 18. Dietrich CF. Comments and illustrations regarding the guidelines and good clinical practice recommendations for contrast-enhanced ultrasound (CEUS)--update 2008. *Ultraschall Med* 2008; 29 Suppl 4:S188-S202.
 19. Dietrich CF, Chichakli M, Hirche TO, Bargon J, Leitzmann P, Wagner TO et al. Sonographic findings of the hepatobiliary-pancreatic system in adult patients with cystic fibrosis. *J Ultrasound Med* 2002; 21(4):409-416.
 20. Dietrich CF, Ignee A, Trojan J, Fellbaum C, Schuessler G. Improved characterisation of histologically proven liver tumours by contrast enhanced ultrasonography during the portal venous and specific late phase of SHU 508A. *Gut* 2004; 53(3):401-405.
 21. Dietrich CF, Jedrzejczyk M, Ignee A. Sonographic assessment of splanchnic arteries and the bowel wall. *Eur J Radiol* 2007; 64(2):202-212.
 22. Dietrich CF, Kratzer W, Strobe D, Danse E, Fessl R, Bunk A et al. Assessment of metastatic liver disease in patients with primary extrahepatic tumors by contrast-enhanced sonography versus CT and MRI. *World J Gastroenterol* 2006; 12(11):1699-1705.
 23. Dietrich CF, Lee JH, Gottschalk R, Herrmann G, Sarrazin C, Caspary WF et al. Hepatic and portal vein flow pattern in correlation with intrahepatic fat deposition and liver histology in patients with chronic hepatitis C. *AJR Am J Roentgenol* 1998; 171(2):437-443.
 24. Dietrich CF, Lee JH, Herrmann G, Teuber G, Roth WK, Caspary WF et al. Enlargement of perihepatic lymph nodes in relation to liver histology and viremia in patients with chronic hepatitis C. *Hepatology* 1997; 26(2):467-472.
 25. Dietrich CF, Leuschner MS, Zeuzem S, Herrmann G, Sarrazin C, Caspary WF et al. Peri-hepatic lymphadenopathy in primary biliary cirrhosis reflects progression of the disease. *Eur J Gastroenterol Hepatol* 1999; 11(7):747-753.
 26. Dietrich CF, Mertens JC, Braden B, Schuessler G, Ott M, Ignee A. Contrast-enhanced ultrasound of histologically proven liver hemangiomas. *Hepatology* 2007; 45(5):1139-1145.
 27. Dietrich CF, Mueller G, Beyer-Enke S. Cysts in the cyst pattern. *Z Gastroenterol* 2009; 47(12):1203-1207.

28. Dietrich CF, Schall H, Kirchner J, Seifert H, Herrmann G, Caspary WF et al. Sonographic detection of focal changes in the liver hilus in patients receiving corticosteroid therapy. *Z Gastroenterol* 1997; 35(12):1051-1057.
29. Dietrich CF, Schuessler G, Trojan J, Fellbaum C, Ignee A. Differentiation of focal nodular hyperplasia and hepatocellular adenoma by contrast-enhanced ultrasound. *Br J Radiol* 2005; 78(932):704-707.
30. Dietrich CF, Stryjek-Kaminska D, Teuber G, Lee JH, Caspary WF, Zeuzem S. Perihepatic lymph nodes as a marker of antiviral response in patients with chronic hepatitis C infection. *AJR Am J Roentgenol* 2000; 174(3):699-704.
31. Dietrich CF, Viel K, Braden B, Caspary WF, Zeuzem S. [Mediastinal lymphadenopathy: an extrahepatic manifestation of chronic hepatitis C?]. *Z Gastroenterol* 2000; 38(2):143-152.
32. Dietrich CF, Wehrmann T, Zeuzem S, Braden B, Caspary WF, Lembcke B. [Analysis of hepatic echo patterns in chronic hepatitis C]. *Ultraschall Med* 1999; 20(1):9-14.
33. Faust D, Fellbaum C, Zeuzem S, Dietrich CF. Nodular regenerative hyperplasia of the liver: a rare differential diagnosis of cholestasis with response to ursodeoxycholic acid. *Z Gastroenterol* 2003; 41(3):255-258.
34. Gaiani S, Bolondi L, Li BS, Zironi G, Siringo S, Barbara L. Prevalence of spontaneous hepatofugal portal flow in liver cirrhosis. Clinical and endoscopic correlation in 228 patients [see comments]. *Gastroenterology* 1991; 100(1):160-167.
35. Gaiani S, Gramantieri L, Venturoli N, Piscaglia F, Siringo S, d'Errico A et al. What is the criterion for differentiating chronic hepatitis from compensated cirrhosis? A prospective study comparing ultrasonography and percutaneous liver biopsy [see comments]. *J Hepatol* 1997; 27(6):979-985.
36. Gebel M, Caselitz M, Bowen-Davies PE, Weber S. A multicenter, prospective, open label, randomized, controlled phase IIIb study of SH U 508 a (Levovist) for Doppler signal enhancement in the portal vascular system. *Ultraschall Med* 1998; 19(4):148-156.
37. Gossmann J, Scheuermann EH, Frilling A, Geiger H, Dietrich CF. Multiple adenomas and hepatocellular carcinoma in a renal transplant patient with glycogen storage disease type 1a (von Gierke disease). *Transplantation* 2001; 72(2):343-344.
38. Hirche TO, Ignee A, Hirche H, Schneider A, Dietrich CF. Evaluation of hepatic steatosis by ultrasound in patients with chronic hepatitis C virus infection. *Liver Int* 2007; 27(6):748-757.
39. Hirche TO, Russler J, Braden B, Schuessler G, Zeuzem S, Wehrmann T et al. Sonographic detection of perihepatic lymphadenopathy is an indicator for primary sclerosing cholangitis in patients with inflammatory bowel disease. *Int J Colorectal Dis* 2004; 19(6):586-594.

40. Ignee A, Gebel M, Caspary WF, Dietrich CF. [Doppler imaging of hepatic vessels - review]. *Z Gastroenterol* 2002; 40(1):21-32.
41. Ignee A, Weiper D, Schuessler G, Teuber G, Faust D, Dietrich CF. Sonographic characterisation of hepatocellular carcinoma at time of diagnosis. *Z Gastroenterol* 2005; 43(3):289-294.
42. Kirchner J, Zipf A, Dietrich CF, Hohmann A, Heyd R, Berkefeld J. [Universal organ involvement in Rendu-Osler-Weber disease: interdisciplinary diagnosis and interventional therapy]. *Z Gastroenterol* 1996; 34(11):747-752.
43. Leen E, Goldberg JA, Angerson WJ, McArdle CS. Potential role of doppler perfusion index in selection of patients with colorectal cancer for adjuvant chemotherapy [see comments]. *Lancet* 2000; 355(9197):34-37.
44. Lyttkens K, Hannesson P, Prytz H, Wallengren NO, Forsberg L. Lymph nodes in the hepato-duodenal ligament. A comparison between ultrasound and low-field MR imaging. *Acta Radiol* 1996; 37(4):521-523.
45. Metreweli C, Ward SC. Ultrasound demonstration of lymph nodes in the hepatoduodenal ligament ('Daisy Chain nodes') in normal subjects. *Clin Radiol* 1995; 50(2):99-101.
46. Mork H, Ignee A, Schuessler G, Ott M, Dietrich CF. Analysis of neuroendocrine tumour metastases in the liver using contrast enhanced ultrasonography. *Scand J Gastroenterol* 2007; 42(5):652-662.
47. Ochs A. Transjugular intrahepatic portosystemic shunt. *Dig Dis* 2005; 23(1):56-64.
48. Piscaglia F, Donati G, Serra C, Muratori R, Solmi L, Gaiani S et al. Value of splanchnic Doppler ultrasound in the diagnosis of portal hypertension. *Ultrasound Med Biol* 2001; 27(7):893-899.
49. Piscaglia F, Gaiani S, Gramantieri L, Zironi G, Siringo S, Bolondi L. Superior mesenteric artery impedance in chronic liver diseases: relationship with disease severity and portal circulation [see comments]. *Am J Gastroenterol* 1998; 93(10):1925-1930.
50. Piscaglia F, Gaiani S, Zironi G, Gramantieri L, Casali A, Siringo S et al. Intra- and extrahepatic arterial resistances in chronic hepatitis and liver cirrhosis. *Ultrasound Med Biol* 1997; 23(5):675-682.
51. Piscaglia F, Valgimigli M, Serra C, Donati G, Gramantieri L, Bolondi L. Duplex Doppler findings in splenic arteriovenous fistula. *J Clin Ultrasound* 1998; 26(2):103-105.
52. Piscaglia F, Zironi G, Gaiani S, Ferlito M, Rapezzi C, Siringo S et al. Relationship between splanchnic, peripheral and cardiac haemodynamics in liver cirrhosis of different degrees of severity. *Eur J Gastroenterol Hepatol* 1997; 9(8):799-804.

53. Rossle M, Haag K, Ochs A, Sellinger M, Noldge G, Perarnau JM et al. The transjugular intrahepatic portosystemic stent-shunt procedure for variceal bleeding. *N Engl J Med* 1994; 330(3):165-171.
54. Sabba C, Ferraioli G, Buonamico P, Berardi E, Antonica G, Taylor KJ et al. Echo-Doppler evaluation of acute flow changes in portal hypertensive patients: flow velocity as a reliable parameter. *J Hepatol* 1992; 15(3):356-360.
55. Sabba C, Ferraioli G, Buonamico P, Mahl T, Taylor KJ, Lerner E et al. A randomized study of propranolol on postprandial portal hyperemia in cirrhotic patients. *Gastroenterology* 1992; 102(3):1009-1016.
56. Schuessler G, Fellbaum C, Fauth F, Jacobi V, Schmidt-Matthiesen A, Ignee A et al. [The inflammatory pseudotumour -- an unusual liver tumour]. *Ultraschall Med* 2006; 27(3):273-279.
57. Seitz K. [Duplex sonographic findings in the portal system]. *Verh Dtsch Ges Inn Med* 1988; 94:560-568.
58. Seitz K, Wermke W. Portal hypertension--current status of ultrasound diagnosis. *Z Gastroenterol* 1995; 33(6):349-361.
59. Strobel D, Seitz K, Blank W, Schuler A, Dietrich C, von Herbay A et al. Contrast-enhanced ultrasound for the characterization of focal liver lesions--diagnostic accuracy in clinical practice (DEGUM multicenter trial). *Ultraschall Med* 2008; 29(5):499-505.
60. Wanless IR. Micronodular transformation (nodular regenerative hyperplasia) of the liver: a report of 64 cases among 2,500 autopsies and a new classification of benign hepatocellular nodules. *Hepatology* 1990; 11(5):787-797.
61. Wermke W. Etiopathogenesis, morphology and hemodynamics of portal hypertension. *Z Arztl Fortbild (Jena)* 1993; 87(12):961-967.
62. Wermke W. Examination technique and findings of ultrasound procedures in portal hypertension. *Z Arztl Fortbild (Jena)* 1994; 88(10):763-772.
63. Wernecke K, Heckemann R, Rehwald U. [Ultrasound-guided thin-needle biopsy in focal liver diseases. II. Benign focal liver diseases]. *Ultraschall Med* 1984; 5(6):303-311.